



Spinal deformities in farmed Atlantic salmon

Andrew M. Silverstone and Larry Hammell

[Author information](#) ► [Copyright and License information](#) ►

This article has been [cited by](#) other articles in PMC.

Abstract

[Go to](#)

Spinal deformities in farmed Atlantic salmon (*Salmo salar*) are often observed in intensive farming systems and result in production losses. Many putative factors have been implicated with the formation of spinal deformities in larger salmon. This condition has been described as broken back syndrome, curvy back disease, and short tails.

Fish were obtained from an Atlantic salmon (*Salmo salar*) hatchery in eastern Canada. There had been no outbreaks of infectious disease in the previous 6 mo and no unexplained mortalities. Salmon smolts (approximately 30–100 g) were being transferred from the freshwater hatchery to marine net pens. During this process, the hatchery staff observed a higher than usual proportion of smolts with spinal deformities ([Figure 1](#)). No abnormal findings, other than spinal curvature, were detected on necropsy of 5 moribund Atlantic salmon smolts.




Figure 1. Photograph of an Atlantic salmon smolt. Spinal lordosis and kyphosis are grossly apparent.

The radiographic findings were spinal kyphosis and lordosis, shortened vertebral bodies, and pathological fractures of the vertebrae. The kyphosis involved the mid-spine, beginning at the 25th vertebral body; decreased rib spacing and collapsed and narrowed intervertebral spaces at vertebrae 18–36, which resulted in the associated intercostal spaces being asymmetric, were observed. The intervertebral space at the transition from kyphosis to lordosis was normal. There was no evidence of bridging callus or periosteal reaction ([Figure 2](#)).

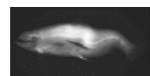


Figure 2. Radiograph of an Atlantic salmon smolt with spinal kyphosis and lordosis.

Spinal deformity is a condition in farm-reared Atlantic salmon, for which individuals are usually culled. Afflicted fish do not swim efficiently, are less capable of acquiring food, are at a greater risk of predation, are more susceptible to physiological imbalances, and, if feral, are less likely to compete effectively for a mate or to defend territory (1). Genetic factors have been thought to play a role. Parasitism is yet another contributing factor (1,2). Several studies have linked various nutritional factors to the pathogenesis of the disease (3,4,5,6,7,8,9). A linkage with pollution exists for spinal deformities in feral fish (1,3,10). Other factors include traumatic injury during husbandry procedures and elevated water temperature during early development. It is likely that the etiology is multifactorial. Reports describe the occurrence of compressed and fused vertebrae caudal to the dorsal fin; compression and ossification of the vertebral joints; and excessive proliferation of collagen, resulting in grossly evident increased thickness of the spinal column. Individual vertebrae have a reduced length and diameter, and the mineral content is 15% to 25% less than that of healthy salmon (11).

The gross findings of kyphosis, scoliosis, and lordosis are consistent with dietary vitamin C deficiency. Depending on the species, fish either lack the ability to synthesize vitamin C or do not produce vitamin C at a rate that allows the formation of physiologically normal cartilage, bone, and connective tissue (7). In a study of vitamin C deficiency in channel catfish (*Ictalurus punctatus*), the findings included spinal deformities (kyphosis, scoliosis, lordosis), a decrease in the collagen content of bone, darkened skin, fin erosion, internal and external hemorrhages, and a reduced rate of growth (7,12). Brittle and weak vertebrae were observed on postmortem examination of the scorbutic fish (7). Histological examination of the tissues circumscribing the spinal cord found hemorrhages in several muscle groups and in the areolar connective tissue. Decreases in functional vitamin C due to exposure to the insecticide toxaphene have been shown to affect the development of skeletal collagen in fathead minnows (*Pimephales promelas*) (12). Supplementary vitamin C ameliorated the condition in dietary deprived fish; the findings of this study also demonstrated the interdependence of the etiological factors (7). The effects of a deficiency in vitamin C on other species of fish were shown to be variable: rainbow trout (*Oncorhynchus mykiss*) did not develop spinal deformities until 20 to 24 wk of age, yet channel catfish (*Ictalurus punctatus*) developed scoliosis and lordosis at only 8 to 10 wk of age (6). Radiographs of vitamin C deficient fish showed that spinal damage was frequently observed caudal to the last rib, lordosis was most often observed at the base of the dorsal fin, and bony exostoses were observed on the vertebral transverse processes (7). Pathological lesions to the skeleton are more likely to occur in rapidly growing animals (osteochondrosis in pigs), so the hypothesis that growth rate may be another risk factor in the occurrence of spinal deformities is plausible (6,13).

In rainbow trout, leucine supplements resulted in grossly evident scoliosis (5). In Scottish perch, (*Perca fluviatilis*), dietary excess of leucine

in combination with a *Myxobolus* sp. infection was associated with the occurrence of vertebral fusion and compression (2). Whirling disease is caused by the histozoic parasite (*Myxobolus cerebralis*). *Myxobolus* is a myxosporean parasite that migrates to the cartilages of the cranium in juvenile fish. The disease manifests as behavioral aberrations, which include chaotic tail-chasing behavior. Spinal disc curvature occurs from damage to the cartilage in the tail (2).

High levels of vitamin A have been observed to cause spinal effects in rainbow trout (7). Spinal deformities and decreased growth rates have been observed in Atlantic salmon when oxytetracycline was added to the diet, while fish in a control group, which were not fed oxytetracycline, did not develop spinal anomalies. Arctic char (*Salvelinus alpinus*) whose feed was laced with oxytetracycline were asymptomatic (9).

Evidence exists of the culpability of heavy metals (arsenic, cadmium, copper, lead, mercury, zinc), bleached kraft mill effluent, and chlorinated benzoquinones as etiological factors of vertebral defects in feral fish (1,3,4,6,11). Vertebral damage resulting from alteration of the muscle action potential has been attributed to heavy metal toxicities (zinc, cadmium). In mammals, the development of renal osteomalacia resulting in decalcification of skeletal bone (Itai-itai disease in humans) has been attributed to chronic cadmium poisoning. Hypokalemic and hypocalcemic states, secondary to cadmium poisoning, may result in both skeletal weakness (osteomalacia) and neuromuscular damage, leading to development of vertebral malformations (1,3,10). Spinal deformities associated with organophosphate, organochlorine, and carbamate intoxications have been reported (1,8,10). In cases of toxicities that culminate in tetanic convulsions, the scoliosis occurs secondary to the effects on the neuromuscular system. Evidence to support the neurological involvement includes the hyperpigmentation observed in the tail (blacktail); the caudal melanocyte patterns are regulated in a neurocompetent fish (10).

In this case, further investigation to determine the etiology of the condition would include vitamin and mineral analysis of the feed for imbalances, microscopic examination of decalcified tissues for evidence of exposure to an infectious agent, and a review of vaccination protocols, including the size of the fish at vaccination, which would be helpful in determining if the lesions were associated with needle trauma or handling by keepers. A review of hatchery records and practices to evaluate the water source and incubation temperature, the feeding plan, and the biomass/fish density might also lead to the determination of contributing factors to the development of this disease.

An extensive study was undertaken in Norway to determine risk factors for spinal deformities in premarket-sized farmed Atlantic salmon (14). Factors at all levels of production; egg, smolts, seawater, and slaughter, were examined. The report concluded that the occurrence of spinal deformities was multifactorial, involving risk factors in the egg, smolts, and seawater stages. Three main findings of the paper were that salinity and temperature, age at vaccination, and weight at "smoltification" influenced the development of deformities. Relative risks were calculated, based on the prevalence of the deformities diagnosed at slaughter.

Smoltification is the process by which a fish living in freshwater adapts physiologically to living in seawater. The primary changes occur in the number and activity level of chloride cells in the gills. Increased chloride cell function allows the pumping of sodium out of the blood to maintain osmoregulatory balance in hyperosmotic environments. There are other physiological changes, but maturation of the chloride cells of the gill is the most significant change.

If the time between vaccination and the introduction to seawater exceeded 3 mo, the risk of vertebral malformation occurring (relative risk = 1.6) was increased. The vaccination factor was likely due to the relative younger age and smaller size of smolts if they were vaccinated 5 mo before being introduced to seawater. Younger smolts (2 mo) may have been more susceptible to the stress of being vaccinated prior to smoltification, due to the mechanical stresses of being handled and of receiving an intraperitoneal injection (14). Based on this finding, smolts should not be vaccinated until 2 mo prior to introduction to seawater (14).

The risk of spinal deformities was doubled in salmon that were raised in fjords versus oceanic sites (relative risk = 1.9). Fish growth occurs at an even rate if salinity and temperature are kept at constant levels. Such fluctuations are minimized in oceanic sites in comparison with fjords. Fish that are at a higher risk of developing malformations may fare better at sites having an ambient temperature and salinity with minimal fluctuations (14).

The risk of spinal injuries has been shown to be reduced if smolts weighing approximately 50 g or less are not introduced to seawater. In the findings of the Norwegian study, the risk of spinal deformities decreased when the weight of the 1-year-old smolts (S1) group increased from 0.047 to 0.103 kg (relative risk = 0.2). One-year-old S1 smolts are introduced to the sea in the spring. Older, larger, smolts (A1, S2) are introduced at different seasons; A1 smolts are 1-year-old smolts that are introduced to the sea in the autumn, and S2 smolts are 2-year-old smolts that are introduced to the sea in the spring. A difference in the occurrence of deformities was not observed in the A1 and S2 smolts. The benefit from increased weight at the time these smolts are introduced to seawater is speculated to be due to their ability to handle the stress of smoltification. Smaller smolts may be at an increased risk, compared with larger smolts, of developing spinal injuries due to the tremendous increase in growth that occurs when they are introduced to seawater (14).

The following practices may reduce the risk of spinal deformities occurring in hatchery Atlantic salmon. Minimize the fluctuation of water temperature, vaccinate the smolts when they are as large as possible, and attempt to produce smolts weighing 100 g or more before transferring them to seawater. Further risk factor studies should be pursued to better quantify the risks of developing spinal deformities associated with management practices. Spinal deformities represent a disease of intensive production in farmed fish. In feral fish, occurrence of the condition represents a sentinel to water pollution. Management factors can reduce the development of this disease in farmed fish. CVJ

Address correspondence and reprint requests to Dr. Andrew M. Silverstone.

Dr. Silverstone's current address is the National Cancer Institute, National Institutes of Health, Department of Experimental Transplantation & Immunology, Building 10, Room 12 C 116, MSC 1907, Bethesda, Maryland 20892-1907, USA. Email: dogtor@mac.com.

References

[Go to:](#)

1. Bengtsson BE. Vertebral damage in fish induced by pollutants. In: Brown JE, ed. *Sublethal Effects of Toxic Chemicals on Aquatic Animals*. Amsterdam, Elsevier: 1975:22–30.
2. Treasurer J. Vertebral anomalies associated with *Myxobolus sp.* in perch *Perca fluviatilis L.*, in a Scottish loch. *Bull Eur Assoc Fish Pathol* 1992;12:61–63.
3. Bengtsson BE. Biological variables, especially skeletal deformities in fish, for monitoring marine pollution. *Phil Trans R Soc Lond, Biol Sci.* 1979;286(1015, Aug. 8):457–464.
4. National Research Council. Vitamins and minerals. In: *Nutrient Requirements of Warmwater Fishes*. Washington, DC: Natl Acad Sci. 1977:18–22.
5. Choo PS, Smith TK, Cho CY, Ferguson HW. Dietary excesses of leucine influence growth and body composition of rainbow trout. *J Nutr* 1991;121:1932–1939. [[PubMed](#)]
6. Halver JE, Ashley LM, Smith RR. Ascorbic acid requirements of coho salmon and rainbow trout. *Trans Am Fish Soc* 1969; 98:762–771.
7. Lim C, Lowell RT. Pathology of the vitamin C syndrome in channel catfish (*Ictalurus punctatus*). *J Nutr* 1978;108:1137–1146. [[PubMed](#)]
8. Mbuthia PG. Scoliosis of farmed rainbow trout (*Salmo gairdneri*, Richardson) in Kiambu District, Kenya. *Bull Anim Health Prod Africa*, 1994;42:111–115.
9. Toften H, Jobling M. Development of spinal deformities in Atlantic salmon and Arctic charr fed diets supplemented with oxytetracycline. *J Fish Biol* 1996;49:668–677.
10. Couch JA, Winstead JT, Goodman LR. Kepone-induced scoliosis and its histological consequences in fish. *Science* 1977;197: 585–587. [[PubMed](#)]
11. Baeverfjord G, Åsgård T, Gjerde B, Holmefjord I. Ryggdeformitet hos laks skuldast ikkje innavl eller genfeil. *Norsk Fiskeoppdrett* 1996;10:34–35.
12. Meyer FP. The pathology of major diseases of catfish. In: Ribelin WE, Migaki G, eds. *The Pathology of Fishes*. Madison, Wisconsin: Univ Wisconsin Pr, 1975:275–286.
13. Weisbrode SE, Doige CE: Bones and joints. In: McGavin MD, Carlton WW, Zachary JF, eds. *Thompson's Specialized Veterinary Pathology*. St. Louis, Missouri: Mosby, 2001:499–536.
14. Vågsholm I, Djupvik HO. Risk factors for spinal deformities in Atlantic salmon, *Salmo salar L.* *J Fish Dis* 1998;21:47–53.

Articles from The Canadian Veterinary Journal are provided here courtesy of **Canadian Veterinary Medical Association**